W28

Reprint from The Ar gy and Radiology,

THE TREATMENT OF PYORRHEA ALVEOLARIS WITH THE X-RAYS.*

By Weston A. Price, D. D. S.,
of Cleveland, Ohio,
Professor of Electrology and Radiology at the Western Reserve University Dental Department, etc.

It is doubtful if any field for the therapeutic application of the Roentgen rays is more encouraging and promising of good results than the treatment of that stubborn malady of the oral cavity which causes the loosening and shedding of so many teeth, usually with much distress and a more or less constant flow of pus. It is commonly called pyorrhea alveolaris, also interstitial gingivitis, phagedenic pericementitis and Rigg's disease. In 1898 I made a series of studies with skiagraphs of the alveolar structure of a few typical cases of pyorrhea alveolaris, noting the diminution of the lime salts by the less density or absence of the bony tissues, and was particularly interested in one case which was especially aggravated. The flow of pus was profuse and the discomfort quite severe and continuous. The teeth, the lower left molars, were quite loose. I made several X-ray pictures of the case at sittings when inserting some fillings in the anterior teeth. The patient was urged to have the pockets and teeth thoroughly cleansed and treated, and an appointment was made for that purpose, but he broke it and was disinclined to make another, stating that the teeth were not worth the time. Some months later he came to the office and stated that for some reason his teeth were very much better, and on close examination I found that the tissues had lost their previous appearance and the presence of pus, which before had been so profuse, was scarcely discernible. The whole condition was very greatly improved. I saw the case frequently for the next year, and although the condition was quite distressing on the other side, this side remained quite free from either discomfort or pus. This case had about five or six exposures. I thought the X-rays might have had something to do with the results, but feared it was only a coin-

*Read before the Cleveland Dental Society, at Cleveland, O., Jan. 4, 1904.

cidence; however, I determined to make a test case as soon as I would have a typical and extreme case.

I finally found such a case where the patient, Mr. H., aged about fifty, was willing to be experimented upon. He had been troubled a great deal for the preceding five or six years, during which time the right upper lateral had loosed and been lost, and the cuspid adjoining was very sore and somewhat loose and with a very profuse flow of pus. He said there had not been a time for years when he would not press a quantity of pus from the cavity every time he would put his finger over that tooth. The centrals were quite badly affected and the right cuspid just below also. About ten to twenty minutes were spent in removing any *readily removable* deposit and debris from all these teeth and an opaque mask was put over his face, being careful always to cover the lower cuspid and expose the upper cuspid root area. The test was to try exposing the worst tooth to the X-rays and protect the rest from them, very particularly the lower cuspid. The patient's business, and probably more than a little his lack of hope for any beneficial effect, made it very difficult to get sittings regularly, but a number of treatments were carefully made from one to two weeks apart, and whether incidentally or not, the pus rapidly disappeared from the upper cuspid being treated and continued with no change for the better around the lower cuspid. The congested and bluish angry gum with its gaping pocket gradually and quite rapidly changed to a pinkish white and the thickening reduced to about that of a normal gingival margin. A very marked change in the condition was that the gaping pocket constricted until the tissue hugged the root quite closely, so that it took perceptible pressure to pass a scaler between the tooth and gums into the pocket. There was a very marked change in the response of the tissues. Before the tooth was very tender to brush and the gums painful. It caused much pain to put an instrument into the sensitive pocket and after the series of treatments this sensitiveness disappeared. The patient described the change as being that before the tooth felt like a foreign substance and an irritant, and afterward felt like his

own tooth. This tooth had no treatment that the others did not have, except the exposure to the X-rays. It is now nine months since the last treatment and there is no recurrence of pus or any of the typical symptoms around the tooth treated, but the lower cuspid which was protected still has its profuse flow of pus on pressure and also tenderness. The upper centrals were generally partially or wholly exposed during the treatments, and while the condition was not aggravated around them to start with, they too were very materially improved. I have had some others watch the results of these cases with me in order that a more correct judgment might be secured, among them Dr. McDill and Dr. Yahres.

Encouraged by this result, but feeling that it might all be due to some other unobserved cause, I tried some very difficult, unpromising cases. Mrs. C., age about sixty, stout and rheumatic, knew of the encouraging results of the last case and begged to have the treatment applied to her teeth. The upper cuspids, particularly the right, were very bad, but her lower centrals and cuspids were worse, indeed very bad. The loose lower incisors had been supported by a splint attached to the cuspids, and the gums about them all were very much inflamed and swollen, and I think the most sensitive tissue I have ever tried to work around. I tried to remove the debris around the roots, but could not go into the pockets. After a few treatments I could work around the cuspids and laterals, but the centrals were still very sensitive. From the first the hemorrhage had been profuse and a dark blue, indicating a very stagnant circulation. I took a skiagraph of the teeth and found the attachment gone almost entirely, even to the apices of the centrals, and decided that the splint was about all that kept them from dropping out, and accordingly removed their attachments to it and easily took them away and replaced them with artificial teeth attached to the same splint.

The treatments were continued once or twice a week until in all about ten or twelve treatments were given, always protecting the very bad upper right cuspid from the rays in order that a good test might be made. The pain was

so much relieved after the treatments that the patient entreated me to make very frequent exposures to the rays. My fear and dread of burning the patient or of over-treating and the difficulty of protecting her and the inconvenient apparatus I then had to use to make the application restrained me from very frequent treatments until I could perfect something better. It is very significant that, though the lady had to come a long distance and was not able to get on and off the cars without considerable difficulty and danger, she would telephone between appointments for permission to come, giving as her reason that her gums felt so much better for a day or two after treatments. The results were that the soreness and swelling and redness, and particularly the presence of pus, were quite entirely removed from all the lower teeth exposed. The gums took a very normal shape and light pink color, constricting about the teeth, and a very signficant condition is that while hemorrhage is produced with some difficulty, it is red blood instead of a dark blue, showing a very marked improvement in the functional activity of the tissues.

The upper cuspid, which was protected from the rays, showed no marked improvement, if any. This was the condition when I left last June for my vacation, and her lower teeth have kept improving since that time. It is a strange coincidence that the upper cuspid, which had exactly the same treatments as these lower teeth, viz., removal of easily accessible debris—except that it was protected from the X-rays—should have fared just like the protected teeth of the last cited case, viz: got worse, while those treated got better.

On my return from my vacation this elderly patient was on hand to have this upper cuspid treated. The flow of the pus was very profuse and the tooth very sensitive to concussion. The inflamed gums bled on the slightest irritation, but a very dark blue blood. No treatment was given except the removal of the accessible debris and deposit and the exposure to the X-rays, and in six weeks the presence of pus was almost entirely relieved and the gums had become quite normal in shape

and color. She left the city at that time and I have not seen her since.

She has lost in the last ten or fifteen years about one-third of her teeth, notwithstanding what she tells me has been very thorough treatment.

The next case I will report was Miss F., age about twenty-eight or thirty, who is under treatment at present. The condition was one of very unusually acute pain and sensitiveness. The pockets were very deep, the first upper right molar was as sore and painful as if abscessed, and in fact, we thought it was until I took a skiagraph of it, finding that there was no trouble at the apices of the roots, but the alveolar process was gone in some places to the last third of the roots. The left lateral was elongated about a sixteenth of an inch or more and very loose, and was so painful to touch that she could not for a long time even bite into bread with it. This tooth had a liberal flow of pus and the hemorrhage was very profuse, but very dark in color. Very little debris or deposit could be removed from it, owing to the extreme painfulness, and I desired to avoid using sedatives or medicaments of any kind in all these tests to avoid sources of error in conclusions. This tooth was considered hopeless when we started and was only treated for an observation of the change of symptoms. By the third or fourth treatment the tenderness of all the sore teeth had gone and a very marked diminution in the pus formation had taken place, and by the tenth treatment the color of the gums was almost normal. A most significant change was in the access to the pyorrhoea pockets, the gum tissue was constricted around the teeth in a most surprising and gratifying manner. No means was used to make rigid the loose lateral, which seemed loose enough to be picked out easily with the fingers. As the patient expressed it voluntarily, "That tooth has lost all its painful tenderness; why, it felt just like something that did not belong there, but now it feels just like my own tooth. Why, I bite into apples or anything and never think of it." This skiagraph (Fig. 3), made when the treatment was begun, shows the depth of the pocket all around the

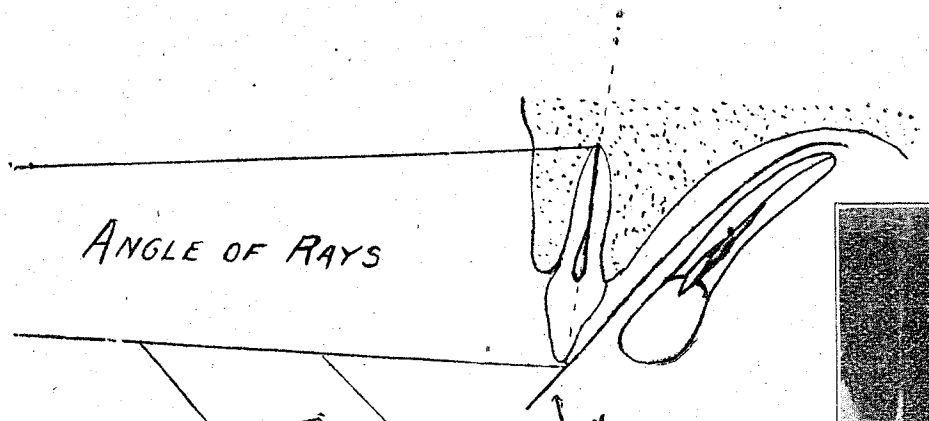

Fig. 1.

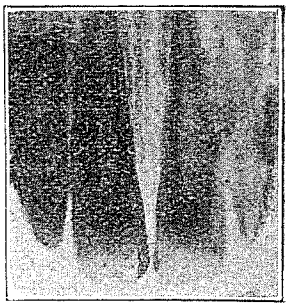

A

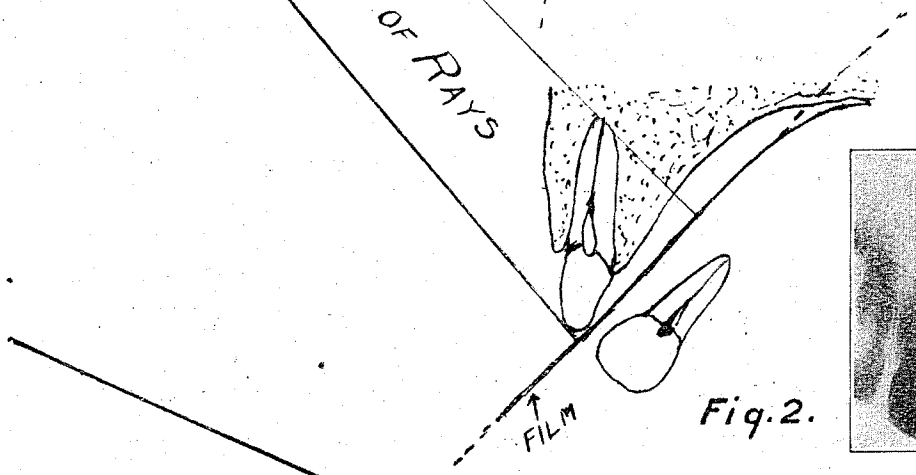

Fig. 2.

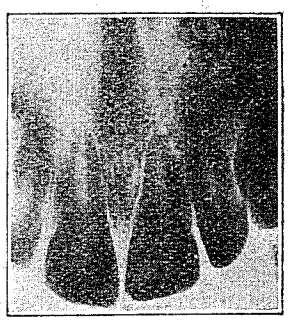

B

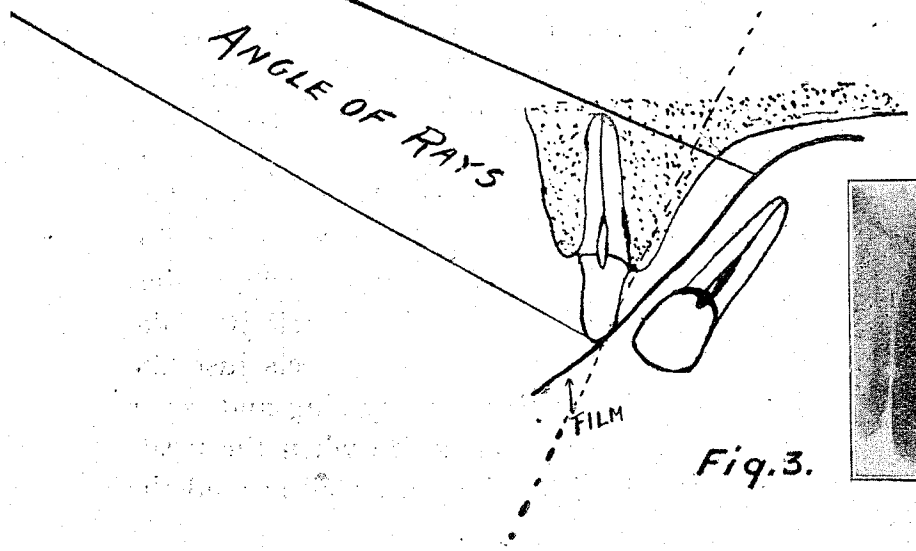

Fig. 3.



C

tooth, and certainly the tooth should properly have been supported for any kind of treatment, but was not in this case to add to the difficulty of the treatment, and to exclude all treatment except the X-rays. The patient has been under this treatment for just eight weeks, having had just sixteen treatments, and for some time has felt no discomfort, she says, from any of the teeth, and all of them are very much improved. They are not cured yet, but very greatly improved.

I have treated less faithfully several other cases for aggravated conditions, and because the experiments were not so carefully carried on and for lack of time will not report them in detail, but in general make this statement, that in no case could I discern any deleterious or undesirable effects, and in no case that could be said to have been treated at all faithfully was there the absence of some improvement in the conditions. In some cases where only one or two treatments were made I could not discern any changes. A couple of cases that got only a very few treatments seemed to improve at first and then go back after the treatments were discontinued.

It is too soon to judge whether the improvement in those cases, apparently greatly helped, will be permanent.

I shall explain my method of making the treatment. When I started this experimenting I did not cover the patient, but treated through the lips and cheeks. Later, in order to protect the patient, I devised an opaque cloth and cut a hole in a blanket of it, and with it covered the patient's head and shoulder, with the hole over the patient's mouth, or part of the mouth. Later I made a tube shield with a mouthpiece, which cut off all the rays from the tube except what would go through the cone and mouthpiece. Now I am using a very small, specially designed tube right against the tissues, with a relatively small volume to allow for the difference in the distance, for the concentration of the rays is inversely in proportion to the square of the distance from the source of the rays.

This new tube which I have devised will, I expect, very greatly simplify and add to the convenience of making these applications. It reduces the inconvenience of the applicatio[n]

very considerably and allows of treating the teeth from the inside as well as from the outside, which has been the only way heretofore, and also protects all parts not desired to be exposed. Since the distance between the source of the rays and the tissues has been reduced in the tube from ten or fifteen inches, as first used, to one-half inch, the time is reduced not in proportion to the difference in the distance, but the square of the distance, and hence if the same volume of X-rays were used, if it took five minutes for a proper exposure at ten and a half inches from the tissues to the anticathode, it would take

$$\frac{5 \times 1}{10 \times 10}$$

, or one-hundredth of five minutes, or three seconds, at one-half inch distance, which distance I can use with this special tube. Notice I said if the same volume of X-rays were used, but we do not and cannot use nearly so large a volume in this tube, probably about one-tenth as great, so we must regulate the time accordingly, say 30 seconds.

I believe thorough, very thorough if possible, cleanliness of the pockets should be secured for any possible kind of treatment of this disease, and suitable washes and sterilizing solutions should be used liberally. Please note that purposely this was not done with any of these cases to exclude errors in conclusion. Since we can with this new form of tube treat the gums from both the inside and outside and at close range, we do not require so high a penetration, and accordingly do not require a large coil. There are very necessary precautions for protecting the patient's lips and hands from the effects of the rays, which are to always have all the tissues not necessary to be exposed protected or shielded by some substance that is opaque to the X-rays. My new tube is provided with this. I have devised an opaque rubber cloth that is very satisfactory for protection, being both flexible and very opaque. All tissues, whether the patient's or the operator's, become more and more easily influenced by the X-rays under continued exposure, the effect being cumulative. This should be borne in mind.

DISCUSSION.

Dr. J. M. Yahres—Through the kindness of Dr. Price it was my good fortune to see the cases referred to in this paper on the treatment of pyorrhea aveolaris with the X-rays.

In the first case, that of Mr. H., I saw it after the second treatment about a year ago. The tooth under treatment, the upper cuspid on right side, had about it a very angry-looking gum tissue of bluish red color, a constant accumulation of pus and very deep pockets.

Mr. H. told me he could by pressure remove pus from the pockets many times during the day. The lower cuspid on the same side was also in a bad condition, but was shielded from the action of the rays so that he might the more positively ascertain the results of X-ray treatment on the upper tooth.

To-day I saw the case again. The gum tissue had lost its angry look and appeared almost normal, the flow of pus had ceased and pocket had decreased from five eighths to about one-eighth of an inch in depth.

When we consider the fact that the last treatment to this tooth had been given nine months ago, that no medicaments had been used and that the lower cuspid which had been shielded from the action of X-rays was in the same condition as before, we cannot but say there has been a great change wrought through the action of the X-rays.

The second case, that of Mrs. C., I saw but once. I therefore cannot say much other than repeat what she said regarding the treatments at that time. She seemed to be delighted with the effects of the treatment and said the only trouble was that the doctor could not give her an appointment often enough to suit her.

The third case, that of Miss F., I saw but twice. The first time about three months ago, just before receiving the third treatment. I found pus, deep pockets, elongation of tooth and extreme soreness, so sore that the patient could not allow anything to touch it when eating. I saw the case to-day and found pus had ceased to flow and patient said all soreness had disappeared and tooth felt as if it belonged to her.

As the doctor says in his paper, he does not claim these cases as cured, and we all know that a year is too soon to judge of the treatment of this condition.

Yet we all must admit that there certainly was a great change wrought in the case of Mr. H., and as the X-ray was the only means used, it must get the credit. We believe Dr. Price has opened a new channel for the relief of the suffering and trust it may lead to a cure of this, our worst enemy, who greets us so often and yet of whom we know so little.

Dr. J. W. McDill—My location in the city and the kindness of Dr. Price has given me the pleasure of watching these very interesting cases. The paper is to a degree a scientific one, and yet it can hardly be classed as a scientific paper as easily as it can a practical one.

In the face of so many failures incident to the introduction of many new ideas and theories one comforting thing crops out in the paper almost as a preface. The essayist modestly lays no claim to cures; in fact, he cites no cases as cured, simply cases benefited, cases seemingly cured either directly or indirectly from the application of the Roentgen rays.

About twelve months ago in the case of Mr. H. the upper righ cuspid presented a typical case of pyorrhea alveolaris

The tooth seemed very loose, extremely sore, especially so when molested. The tissues around the tooth were highly inflamed, quite badly receded and had lost their attachment; in fact, so much so that an instrument could be inserted along the root for more than half an inch.

This operation caused a profuse hemorrhage. Pressure upon the parts adjacent would always bring a flow of pus. The right lower cuspid presented almost the same appearance.

Without removing much of the debris or calculus from the upper cuspid the X-ray was applied. During this procedure the lower cuspid was protected with a special opaque cloth, which prevented action of any kind upon it.

After the lapse of twelve months the upper cuspid tooth seemed to be in a normal condition.

Inflammation having disappeared, the tooth seemed tight in

the process, the tissues seemed perfectly attached about the gingival margin, precluding the possibility of introducing an instrument at all places.

The pus had entirely disappeared and what blood did flow was of a healthy red color, while before it was of a dark bluish tinge. The lower cuspid, which had been protected from the X-rays, was in even worse condition than eight months ago.

The case of Miss F. was very similar to the former. The tooth in question being a left upper lateral incisor, very loose, a large quantity of pus about the root, tissues highly inflamed and elongated one-sixteenth of an inch. An instrument could be inserted almost to the apex of the root and the sensitiveness interfered very materially with mastication. Biting into an apple, as Miss F. said, caused excruciating pain.

As before, without removing much of its debris or calculus, the tooth and tissues adjacent were exposed to the X-rays.

The treatment thus far has been very gratifying indeed, as the tooth now seems tight, the tissues are in the normal condition. The hemorrhage is of a healthy nature. The soreness has disappeared. An instrument is inserted with difficulty above the gingival margin, and while the tooth is still elongated, much can be done by placing it in its normal condition by the use of some rigid staying appliance.

I trust these may develop into permanent cures instead of only giving temporary relief, and thus aid us in coping with a very troublesome, obstinate and discouraging condition which we so often find.

