22

W 31

ELECTRICITY

WHY IT SHOULD BE TAUGHT IN DENTAL COLLEGES, AND HOW

Read before the Institute of Dental Pedagogics, at Chicago, December 29-31, 1902

BY

WESTON A. PRICE, D. D. S., M. E.

Professor of Applied Electricity
in the Dental Department,
Western Reserve University

(Reprint from DENTAL DIGEST, November, 1903.)

ELECTRICITY—WHY IT SHOULD BE TAUGHT IN DENTAL COLLEGES, AND HOW.

BY WESTON A. PRICE, D. D. S., CLEVELAND. READ BEFORE THE INSTITUTE OF DENTAL PEDAGOGICS, AT CHICAGO, DEC. 29-31, 1902.

Let us approach this subject with a few simple deductions. Why do we have dental colleges? To equip men and women to properly practice dentistry. Why do we practice dentistry? To serve humanity. What should we teach in dental colleges? That which will equip men and women to best serve humanity. You will all give hearty assent to these simple deductions and grant that they are good logic, but I am now going to make a statement with which many of you will not agree. Before doing so I wish to remind you that teachers are consistent thinkers, and that as such you have that important fundamental virtue of being able to withhold judgment and weigh without prejudice the arguments on their merits. I do not make this statement to arouse discussion, but to bring out what to me is a fact, and possibly I have some right to strong convictions on this subject. It is this—*There is to-day no one subject taught in our dental colleges that will enter so largely and frequently into the best possible service that we as dentists can render as electricity.*

There are scores of electrical processes and devices that excel all others of which the profession generally is ignorant, and but few could use same intelligently because of their lack of the necessary electrical knowledge. One of the most rapid ways of presenting the evidence to sustain the above assertion is to take you to the busy office and there observe in detail the application of our fund of dental knowledge in the rendering of the best possible service to our patients in a day's work in actual practice.

The first patient we find in the office on arriving in the morning is Miss S., age sixteen. She had no appointment, but is suffering intensely from a toothache, as she calls it. Now let us see what subjects taught us in the dental college will help most in rendering her the best possible service. What are the symptoms? Chiefly pain, several teeth tender to touch, each with large fillings, no definite history, no swelling, no special difference in their response to thermal changes. What is the best service we can render that patient? Certainly it is to relieve the pain as soon as possible, and do it by removing the cause. The question in hand is diagnosis. Try Materia Medica, what assistance will it offer? Practically nothing in this case. Anatomy will certainly help in the diagnosis. Bacteriology offers nothing. Pathology makes essential suggestions, which are, that probably it is either pulpitis, or pericementitis from



No. 1.

a dead pulp, or a faulty root filling. Chemistry offers nothing; Prosthesis, nothing; Dental Jurisprudence, nothing; Histology, nothing; Electricity, several excellent things. That which will help us most is to establish quickly whether or not the pulp is dead in any of these teeth. Thermal changes gave indefinite results. Nothing will tell you so quickly and truthfully and painlessly as an electric current. Transillumination with electric light may show the root fillings, but we have a surer method. Quickly dry the fillings and place a cottonoid pad against the cheek, touch a filling in one of the teeth with an electrode attached to the cataphoric outfit, and carefully turn on the current until the patient feels a slight sensation like warmth or cold, not pain, and note the amount of current indicated by the milammeter—.05. Test another tooth—.07; test another —.9. You have it almost to a certainty that this first permanent

molar is dead. It takes eighteen times as much current as the first tooth tested. What is the history—is this tooth dead, and are its roots filled? Patient does not know, neither does the dentist. Ask your Anatomy, it cannot tell you; ask Materia Medica, nothing; Bacteriology, nothing; Pathology, nothing; Prosthesis, nothing; Chemistry, nothing; Dental Jurisprudence, nothing; Histology, nothing. Here is where you will have to stop and use counter-irritation to cover your ignorance, for which you no longer have an excuse, or ask Electricity—it alone can tell you. Just a one-to-

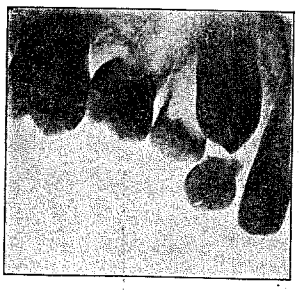

No. 5—*a*.



No. 5—*b*.



No. 5—*c*.



No. 5—*d*.

three-seconds exposure from the ever-ready X-ray machine, and twenty or thirty seconds more to develop the bromid paper enclosed with the film, and you have all the information before you to study in detail. See case No. 1. There is a splendid root filling in the palatal root, and also in the disto-buccal root, but the mesio-buccal root has been drilled through and filled through its side, and has a large area of absorption about its apex, extending forward to the second bicuspid. Thus you know the whole story in a few moments, better than you could by all other means at your disposal

combined for any possible length of time. Let me ask just here how many of you do it in that way, and if not, why not? But some time when you have more leisure, think out the whole history of that case without this exact information.

The diagnosis is perfect, now for the treatment. See picture No. 1. The relief of the pain is now simple because we know it is due to pressure from confined suppuration, the location of which is ascertained. You may drill through the filling with a steady running and quiet electric engine, the best available kind by far, and open only the mesial root, dissolve out the root filling, and give relief, which you would probably do if you knew only that the trouble was in this root without knowing that you would leave the irritant still in the tissue beyond the root. Knowing the exact condition you would



No. 6.



No. 7.



No. 8.

better open through the process at once, through which opening you will later amputate the apex of the root. Most of the patient's pain was relieved by the sedative effect of the X-rays. With removal of the pressure the relief is soon complete. You have been able to do exactly the right and best thing for the patient, and it has taken fifteen minutes altogether.

Suppose you should decide to induce absorption of the pus, how could you best relieve the pain? Vigorous counter-irritation may do this in time. For this you must summon to this part an extra number of the white blood corpuscles, for which iodin has special properties. How much is absorbed by simply painting it on the surface compared to applying the negative pole of your cataphoric apparatus to it and carrying it in by electrolysis? There is certainly no comparison in the efficiency of these two methods, yet how many do it in that way, and why? But suppose the pain still continues,

what more can you do? Will you send the patient away with a sweet promise? No. The pain in almost any condition can be relieved by the positive pole of a galvanic or static current. Dr. William Rollins of Boston uses the latter very extensively.

The next patient, Mr. B., a busy man of thirty years, who had the first appointment, does not regret seriously the loss of ten or fifteen minutes, and we proceed. He has been too busy to go to the dentist before, and he dreaded the ordeal so much, but Nature's monitor sounded the note of warning and he reluctantly heeded. We find he has several very sensitive cavities. For making a thorough examination we use an electric illuminating device, which makes every corner as light as day, but no glare reaches the operator's eyes. What is the best possible service we as dentists can render this



No. 9—*a*.



No. 9—*b*.



No. 9—*c*.

patient? Certainly it is to give him the best possible fillings with the minimum of pain and discomfort. It is a cold morning, so you turn on the electric footwarmer (if it were a hot summer's day, the electric fan), for he is nervously cold. He is dreading the excavation of that second right superior bicuspid and also the cuspid, for both have large cavities and have troubled him greatly. He also has cavities in the left lateral and cuspid and first bicuspid. The rubber cloth is punched for all these, but is put over only the right bicuspids and cuspid, and the second bicuspid is dried carefully with a steady mild stream of warm air, just blood heat, from an electrically heated compressed air syringe. Since one of the simplest anesthetics we have is warm air, we slip over the handpiece a nozzle conveying it, so that a stream of warm air is delivered directly into the cavity onto the bur, thus dispersing the chips as they are cut.

This device has a double advantage, for the source of heat is also a source of light which is reflected directly into the cavity, but not visible to the eye.

Presently we reach very sensitive dentin, which however must be removed for the proper formation of the cavity. We must anesthetize that cavity if we are to render him the best possible service, and we must not produce pain in doing so. Let us go over our college curriculum again for a painless remedy. Anatomy has none, Materia Medica will help us locally but is not satisfactory either in thoroughness or freedom from pain in application. Bacteriology cannot help us, nor Pathology, nor Physiology, nor Prosthesis, nor Chemistry, nor Dental Jurisprudence, nor Histology. Here is where ninety-nine out of every hundred dentists fall down and acknowledge



No. 13.



No. 16.



No. 17.

their inability to render the best possible service, by causing the patient to submit to the ordeal they would go to any trouble themselves to escape. But thanks to the last years of the Nineteenth century and first of the Twentieth the dental profession has to-day a means for thoroughly and painlessly desensitizing these sensitive teeth without loss of time on the whole to either the patient or dentist, but with a decided saving of time to both if properly used. Cataphoresis properly applied is a veritable Godsend to both the patient and dentist, for with it the latter as well as the former is relieved of nine-tenths of his nervous strain. We make the application in the sensitive bicuspid, and it takes only one or two minutes to insulate the cavity and start the application, which takes from ten to thirty minutes, usually not more than fifteen or twenty minutes. While this is going on, and entirely painlessly, we proceed to open up the

large distal cavity in the adjoining cuspid. We know just how anesthesia is progressing by the milammeter, which also tells whether the insulation is perfect or not. We do not find this cuspid cavity very sensitive, but after removing the debris and decay we discover a large exposure of the pulp, not freshly made. This pulp must be removed and the root filled. To the patient this is one of the most dreaded operations, and rightly so. He does not know it is exposed, though he is fearful that something is serious in that tooth, for it has troubled him greatly. We adjust the dam on the anterior teeth, exposing more cavities which we open up, meanwhile frequently increasing the current on the right bicuspid, but never producing any pain by so doing.

By the time we have opened up these cavities the bicuspid is



No. 18.



No. 20.



No. 21.

anesthetized, and we change the flexible electrode with cocain solution from it to the cuspid, and proceed to excavate the bicuspid absolutely without pain and while anesthetizing the cuspid. Having prepared this cavity to our liking, which takes only three or four minutes or less when the tooth is thoroughly desensitized, to prevent the conduction of thermal changes we insert an insulation, cement or other material, over the floor of the deeper part of the cavity, where, by the way, we rarely have to do much drilling beyond the removal of decay, and insert a large compound filling of gold, finishing off with gold and platinum. These are annealed in an electrically heated annealer, because it is far superior to any other kind. By the time this gold and platinum filling is completed, and in fact long before, the cuspid pulp is entirely desensitized, but it will do no harm to allow the current to run until we are ready, provided the cotton

does not get dry or we use too much current, thereby setting up an irritation about the tooth, but the latter is impossible because of our milammeter. We remove this cuspid pulp on a broach, but before doing so shift the cataphoric application to the four approximal cavities in the left lateral, cuspid, and first bicuspid. The patient knows nothing of the pulp having been removed, unless we choose to show him to establish his confidence that we can work without hurting him.

If there were any possible doubt of the entire pulp being removed we would not fill at once, but being certain that it is, we proceed to prepare the root for filling. Its position is a hard one to see into,



No. 22.

being a distal cavity, so we adapt a simple electric illuminating device which is not in the least in our way while working, nor is its source of light directly visible to the eye. With this we can continually see the pulp chambers and canals in any posterior tooth quite as plainly as we can a well exposed anterior canal. This next step is where from fifty to seventy-five per cent of our root fillings fail. We do not thoroughly dry, sterilize, and fill the roots. I know what I am talking about, for I have X-ray pictures of nearly a thousand of all grades, good, bad, and awfully bad—alas, mostly the last two kinds. We must dry the tooth thoroughly to the apex, which can best be done with an electrically heated root-canal dryer. By the time this canal is properly filled the other cavities are ready

to excavate, but certainly they would have different resistance and hence would not all be perfectly anesthetized at the same time, so we will permit the application to remain until we have filled the cuspid. This being done, we quickly and painlessly prepare all four of these cavities and insert temporary stopping, properly warmed in an electric gutta-percha warmer, because it is the best. These we leave until the next sitting, at which time we insert these four gold fillings while electrically anesthetizing four more cavities in the bicuspids and molars. The total extra time consumed in making the cataphoric application to all these teeth did not exceed ten minutes, and you can judge the amount of time actually saved in excavating them.

I have not been painting an ideal picture but a case from prac-



No. 23.



No. 24.

tice during the past week. The patient entered the chair with such dread and fear that the perspiration stood out on his forehead, but after all the work recorded above, namely, the preparation of six very sensitive cavities without the least pain, the removal of one exposed pulp, the insertion of a root-filling and two large fillings, he wanted to know why I did not go ahead and finish all the teeth, that he was perfectly willing, but I had to tell him his time was more than up. I need not dwell upon his extreme gratitude, you know human nature well enough to judge of that. You could hardly put a money value upon it.

The next patient, Mrs. M., aged forty, calls for the treatment of pyorrhea. This condition had been recognized years ago, but she had been assured that nothing could be done to better it. How can we best serve this patient? Going over our college curriculum

again we find exceedingly little assistance. Materia Medica and Pathology can help us a little, but we finally go to work and remove the deposit from every surface of those teeth, and though we apply agents to the tissues, the mechanical cleaning of the surface is nine-tenths of the good we accomplish. Now here is where electricity comes in to assist when all else fails. True, the deposit must be removed, but the combination electrically heated stream of compressed air and powerful illuminating device will aid us greatly in this, but when we have mechanically cleaned the surface of the teeth we have only gotten ready to treat the disease. How can we restore the tissues involved to their normal functions? Materia Medica, nor any nor all of our college courses can do it. In my hands no treatment has been so successful as the X-rays and elec-



No. 25.



No. 26.



No. 27.

trolysis. For the latter I use electrodes made of tin, copper and zinc, in a solution of trichloracetic acid in the pockets. The tone of the tissue is improved at once and the results are more permanent and satisfactory than by any other method I have seen. The presence of pain is removed after the first or second application, and if the treatment is occasionally followed up I find little or no tendency to recurrence.

A new light has dawned upon the sufferers from this disease, of which it is too early to say that it will positively cure. Some of you may not know that cancer, sarcoma, carcinoma, lupus, and practically all malignant growths which are a diverted form of cell proliferation, are benefitted and many are apparently entirely cured by proper treatment with the X-rays. On the hypothesis that pyorrhea so-called is an allied condition of diverted cellular function,

I treated some cases experimentally. It is too soon to say positively about a cure, though I have many cases which are exceedingly encouraging, and I have more faith in it to-day than any other treatment. My first case was about three years ago, and as yet there has been no recurrence. I have a number of cases where there has been cessation of pus after two or three applications. There is great reason for hope from this treatment, but I say frankly it is too complicated and exacting for the untutored profession of to-day to hope to apply successfully without study.

After luncheon our first patient is Miss M., who made an appoint-



No. 28—*a*.



No. 28—*b*.



No. 28—*c*.

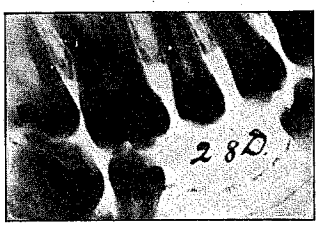

No. 28—*d*.

ment by mail. She has come from a neighboring town to have a broken lateral crowned, and she must have the new one in place to return. The pulp is alive, and on removing the remnants of the gold fillings we find the tooth structure extremely dense and very sensitive. The pulp must be removed at once, and painlessly, as the patient is not physically able to endure pain, though willing if necessary. Can the graduate of any dental college in the world to-day give her the best possible service without electricity? The pressure method will not serve, as the dentin is too dense, but with cataphore-

sis in from twenty to thirty minutes the pulp is entirely removed and without a particle of pain. You have gotten everything ready in the meantime for making a porcelain crown over a platinum post and jacket. Again you come to electricity for the ideal oven which makes it possible for the crown to be built up, baked and artistically stained to match the more worn incisors. The patient leaves the office with the new crown in place, a work of art, for it is the concealment of art, just an hour and a half after entering—an accomplishment absolutely impossible without electricity. This also is a case from actual practice within the last ten days.

The next patient is a boy, fifteen years of age, who presents for correction of the malposition of his teeth. He has an intruded superior bite, the deciduous molars are still in the arch, as is also the deciduous cuspid. Why have not the permanent teeth erupted? where are they? and did they ever form? are questions that must be answered. You cannot safely move one step toward the correction of this condition until you know. Ask Anatomy and it replies yes, precedent says they are there, but just a little delayed. Too indefinite. Ask your whole curriculum, and you get absolutely no assistance. Roll round the ever-ready X-ray table and take a peep with the mouth fluoroscope, or, better yet, quickly make a couple of exposures each from one to three seconds, and in less than two minutes you know it all, as you have the bromid paper skiagraph before you to study. Both bicuspids are missing on the right side, see skiagraph No. 5, and both are present on the left, but the roots are not more than half formed. One left superior bicuspid is missing. The permanent cuspids are both formed, but the right one is malposed, its apex being directed toward the lateral. There is as much superiority in your ability now over what it was before to render good services to that patient as daylight is better than darkness. This a typical case from practice.

The next patient is an elderly lady suffering from chronic neuralgia. Symptoms typical of an obscure irritant. Where and what is it? The best possible service to the patient will find it. Don't treat indefinitely in a process of exclusion, but find that irritant. The teeth are apparently normal, though none is firm. Try transillumination for detecting the presence of pus in the antrum. Note that absolutely no light but electric will do for this. Place the ten-candle-power low-heating lamp into the mouth in the darkened room

and you get a definite shadow under the right orbit. It is exceedingly suggestive. You ask, What is the cause of that fluid in the antrum? No. 6. Ask your curriculum and you get no answer. Take a skiagraph and you find an abscess from a bicuspid discharging into the antrum. This root has a very imperfect filling. You are now ready to render the best possible service, indeed, you have already rendered it, diagnosis being almost everything in such a case.

The next patient presents for treatment a chronic abscess with a fistula over the crowned lateral. The history is long enough, alas, too long—troubling for five years. Dr. A. wanted to extract, Dr. B. said he had tried in vain to cure it, which was evident. What is the trouble? The profession of yesterday answers, it is an incurable case. But why? What is the condition? Ask your old college



No. 29—*a*.
Age, 14 Months.



No. 29—*b*.
Age, 28 Months.



No. 29—*c*.
Age, 3 years.

professor. Which one? Ask them all. They all shake their heads, so hang up your curriculum again and ask electricity. Take a skiagraph. (See No. 7.) It shows exactly the condition, which is extensive absorption of and about the apex, but the tooth is by no means incurable. Amputate the apex and remove all the diseased portion.

The next patient presents a putrescent pulp and blind abscess, which you will best treat by electrolysis of silver nitrate and other dissolved salts.

Just so I could fill in every hour of each day for a week, with no two cases alike, if time would permit. For example, I would present typical cases of neuralgia from pulp nodules, and their diagnosis with the X-rays. See skiagraph No. 8. Neuralgia from excemento-

sis and its diagnosis with the X-rays. See skiagraph No. 9. Also its treatment with the X-rays, which is proving very helpful and promises to be very successful. The treatment of neuritis and painful neuralgia by raying with the X-rays, giving most satisfactory relief from the pain. Treating erythema, lupus, rodent ulcer, and cancer about the mouth with X-rays, with relief of all itching and apparent cure. Relieving the pain of acute abscess by exposing to the X-rays. The detection of decay beneath fillings with the X-rays. Nos. 1, 6 and 13. The detection and location of typical pericemental abscesses where the pulps are alive. The cure with X-rays of chronic abscess with fistula, where tone of tissue is abnormal even after the irritant is removed. The locating of galvanic currents from fillings, producing neuralgia and pulpitis. Showing the cause of resorption of roots of permanent teeth by unerupted teeth. Nos. 16 and 17. Faulty root fillings that pass beyond the apex. No. 18. Broken drills and broaches in teeth. Nos. 20 and 21. Diagnosing tumors which contain teeth. Nos. 22 and 23. Inlocked bicuspid. No. 24. Resorption of implanted root. No. 25. Impacted third molars. No. 26. Fractured roots. No. 27. Malposition and regulation before eruption. No. 28, a, b, c, d. Studying tooth development. No. 29, a, b, c. Cases of impacted missing cuspids. No. 30, a, b, c, d. I have hardly time to open the door to this vast subject, which is almost a new science sweeping into the practice of dentistry.

Perhaps you say cataphoresis is a failure, or is more trouble than it is worth—the X-ray pictures speak for themselves, but you give us only your word for the efficiency of cataphoresis. What are the facts? Cataphoresis came before the members of the profession were capable of correcting or even detecting the causes of their failures, which were primarily due to absolutely inefficient apparatus, and secondarily to inability to fulfill the requirements of the laws of the forces with which they were dealing and the conditions under which they were using them. To-day the apparatus has been so perfected that the first named difficulty has been entirely overcome, and all that is needed now is intelligent application. Naturally and rightly you demand proof for this statement. To-day there are over thirty of the leading dentists of Cleveland using it successfully. Their carefully expressed opinion is of great value at this time. In response to the question, "Does cataphoresis in your opinion enable

the dentist to render materially better service to his patients?" I have the following replies: Dr. Spargur, Cleveland, writes: "In my opinion cataphoresis in the hands of intelligent, careful operators is a complete success in nearly every case where its use is indicated. My experience goes to show that much better service can be rendered in all cases where sensitive conditions prevail, always providing of course that the cavity can be isolated and the field of operation properly insulated. The mental and physical strain on both patient and operator is reduced to a minimum, and the dread of the dental chair greatly lessened in our patients. Personally, I would not know how to keep house without it." Dr. D. H. Ziegler writes: "I am really afraid to answer your communication for fear my enthusiasm will carry me away. Honestly, I would not take $1,000 in cash for my



No. 30—*a*.



No. 30—*b*.



No. 30—*c*.

outfit if I could not replace it, for the simple reason that I can render better service to my patients with more comfort to myself, and needless to say, to the patient. The subject should be taught in our dental colleges on as broad a basis as dental anatomy, pathology, etc. The two subjects named are probably the most important in the dental curriculum." Dr. William Rollins, Boston, writes, "I should say that an apparatus for the electric numbing of sensitive dentin by cocain was indispensable." Dr. R. Ottolengui, New York, writes, "In regard to cataphoresis, while I believe that its use has been rather sporadic, there is no doubt that its usefulness is most patent, and there is little question that had the dental profession a greater knowledge of electricity, cataphoresis would have obtained a firmer hold as a necessary part of dental practice." Dr. W. T. Jackman, Cleveland, writes: "I believe that students should be taught the use

of electricity cataphorically for the reason that the hypersensitive patient must or should have electricity so applied." Dr. H. C. Kenyon, Cleveland, writes: "Cataphoresis not only enables me to render better service to my patients, but it enables me to give much service that would otherwise be out of the question. I make some failures with cataphoresis, but I am convinced that the blame for these is not to be laid to it nor to impossible conditions presented in the cases, but to my ignorance of the subject of electricity in general and of its application to dentistry in particular. Hence I argue for a more thorough course in the colleges. I think the place of electricity in the coming four years' course is just as important and should be just as well filled as bacteriology or dental medicine." Dr. E. B. Lodge, Cleveland, writes: "It must be conceded that the best equipped dental office of to-day is the one installed upon a basis of electricity. Cataphoresis should be one of the agencies at the hand of every dental operator. The experimental stage of the application of electricity being over, and the use of that agent being now safe and exact, we may well feel only partially equipped if our offices have not the perfect dental appliance. Can we render materially better service by the aid of cataphoresis? Yes. When a dentist is able to excavate an otherwise sensitive cavity without giving pain to his patient he suffers less with his patient and is therefore able to accomplish better and more quickly the ends necessary to make a good operation."

I think we have established that a large proportion of the best service we can render our patients is by and with electrical processes and devices. Now how is the dentist to become able to use them? Does he require a special knowledge to do so? Yes, he certainly does. An understanding of electricity and its wonderful behavior can be secured only by hard study. It does not come to any man by instinct. The average man can work it out for himself from books, but not without a great deal of hard study and experimentation. Then how must he obtain this understanding? He should see the various phenomena demonstrated and note their relation and causes and effects, and experimentally produce not only the various phenomena but also the apparatus to produce them. This means a thorough course in college. The coming generations of dentists should have this knowledge, because the present one has

left largely unused the proper application of electricity to dentistry, owing to not having a knowledge of the subject.

Someone may say, but the dental profession of to-day is not so ill-informed on the subject of electricity. The best persons to ask are the makers of electrical dental goods. One prominent dental manufacturing concern writes in reply to this question, "We find as a general thing that when we wish to sell electrical goods we are compelled first to teach the customer what we know about electricity. It is a common expression among the manufacturers of electrical goods that they must make same 'fool-proof.'" Another company writes: "We find that the best informed dentists in electrical appliances have but an imperfect knowledge of the fundamental laws pertaining to electrical science. We meet but few men who have any correct knowledge of the practical application of same, and the vast majority admit having no understanding of the subject whatever. Frequently men hesitate to adopt the use of any electrical appliances because they have a fear of them and cannot appreciate any difference between a high tension line of several thousand volts and a battery of a few volts, and so consider anything electrical to be dangerous. We find that little care is ever given to electrical appliances, because they are not understood and men prefer to leave them alone. Where an effort is made to keep a machine in good order the work is often misapplied. We have found it necessary to so construct and design all machines that they will continue to give good service with minimum care. Ninety-five per cent of the repairs we make would not be necessary did the owners possess a due appreciation of the requirements of the articles bought. In ordering, the mistake is frequently made of specifying a direct current motor when an alternating current machine is wanted, or vice-versa. We should indeed like to see someone publish a book that would enable the profession to gain some of the practical and theoretical knowledge pertaining to dental electric appliances."

There can be no doubt that the dentist of to-day should have and the dentist of to-morrow must have a thorough knowledge of dental electricity. If time had permitted I intended to tell you of some of the coming fields for applying an electrical knowledge in dentistry, particularly the electro-chemical phase of filling materials. There is a new universe opening up just here in dentistry. Also

the production of pain in our operations by static currents which pass from our bodies and the dental engines, etc., to the patient through the instrument and cavity, producing much pain, and how they can be detected and prevented. Also many new electrical devices and new practical applications of electricity in dentistry, like the sharpening of burs almost as good as new at almost no expense, but there is not time.

There is not time enough left to present in detail my idea of the methods by which electricity should be taught in dental colleges, but in brief it is as follows—Since electricity, mechanical work, and chemical reaction all have an equivalent, and the measure of one can be expressed directly in the equivalent units of the other, it becomes necessary for the student to study their relation and dependence on each other as they are presented in a general study of physics. This will be his foundation for all later intelligent study, and without it he cannot apply his knowledge to everything and everything to his knowledge. There is a future for the coming dentist that we cannot now even conceive, and above everything else he must have a good foundation. While this course in physics should be general, it should also be specially dental, that is, emphasizing the departments that will be most used, and should be largely a demonstrated lecture course. This should be followed by a practical laboratory course in applied physics, chiefly electro-physics and electro-chemistry. In this course the student should be taught and shown the detail of construction of all the principal apparatus he will afterward use, and he should be required to design and construct working models, to see that he understands perfectly both the principles of construction and the laws of cause and effect involved. This is very essential. In this practical course the student should make with his own hands and from his own designs a working permanent magnet and electro-magnet, a dry cell, a wet cell, a storage cell, a small motor, a small dynamo, a rheostat, a galvanometer, a small electric furnace, a small induction coil, a small faradic coil, an X-ray screen, prepare dental X-ray films, etc.

He should next receive a course in the practical application of electricity in practice, as in electro-therapeutics, electro-chemistry, etc. In this course he should be taught in detail the technique of applying cataphoresis for the desensitizing of sensitive dentin, the removal of pulps, etc.; the application of electrolysis in stimulating

pyorrhea pockets, in carrying medicaments into all tissues for disinfectant, anesthetic, and stimulating effects, as in abscesses and putrescent roots; the treatment of pyorrhea with the X-rays; the checking of excementosis by raying with the X-rays; locating missing teeth, faulty root filling, abscesses, pulp nodules, etc., with the X-rays; aborting abscesses with static current; how to use the antrum illuminator; the care and use of the root-canal dryer, the various mouth illuminators, the electric furnace, electric motors, electro-plating, X-ray tubes; making X-ray pictures, care and use of galvanic cells, etc. These three courses should be extended over the sophomore, junior and senior years in the order named. If he could get the general physics before entering college it would be decidedy an advantage.

Gentlemen, we have a sacred trust under Almighty God. To us is given the great responsibility, not simply of the destiny and qualification of the dentist of to-morrow, but the pain or joy of millions of people. May an infinite wisdom direct those upon whom the enormous responsibility shall fall of deciding the curriculum for the coming four-year course.